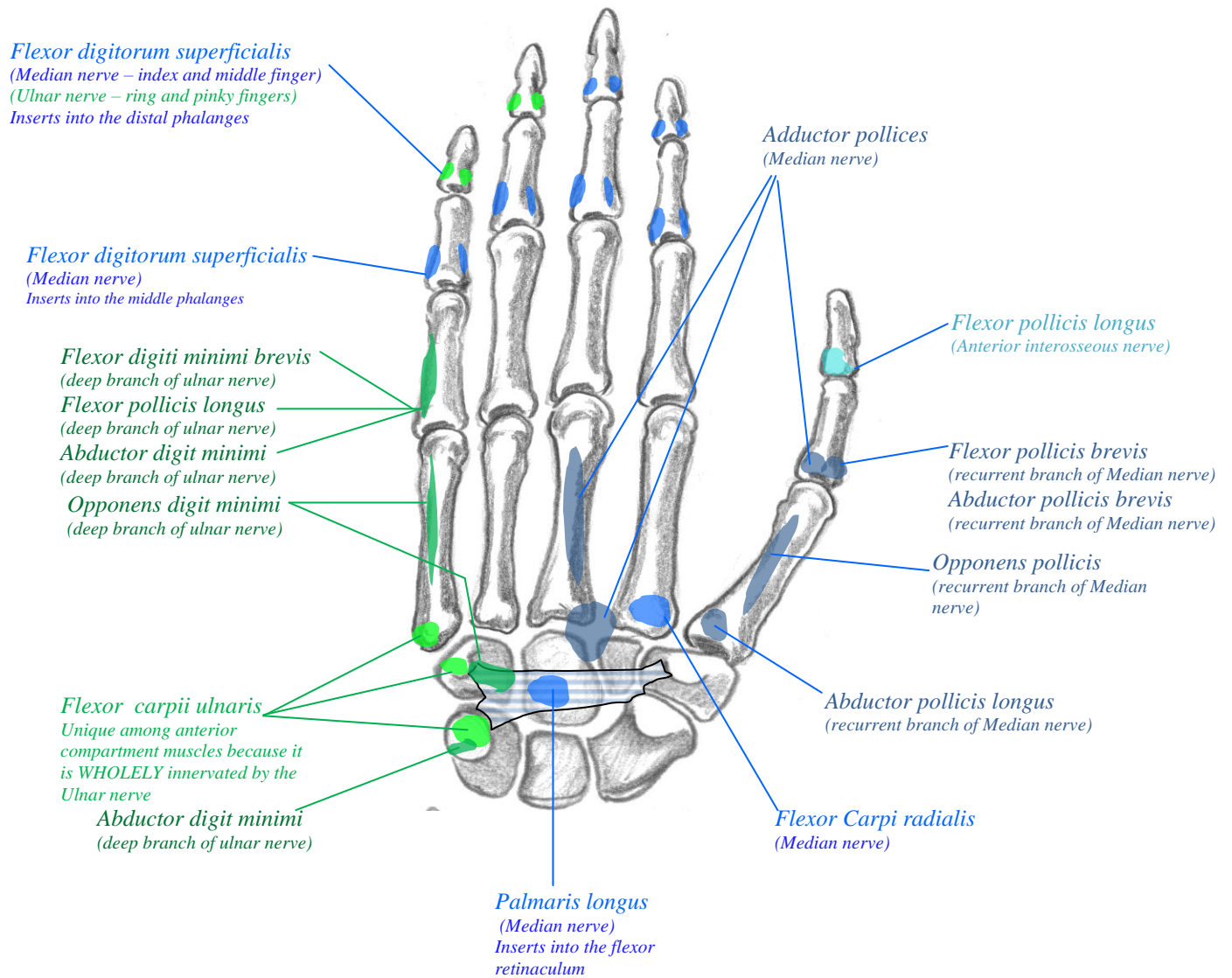


The carpus and hand: palmar surface



Opponens pollicis brevis, abductor pollicis brevis and flexor pollicis brevis all originate from the flexor retinaculum