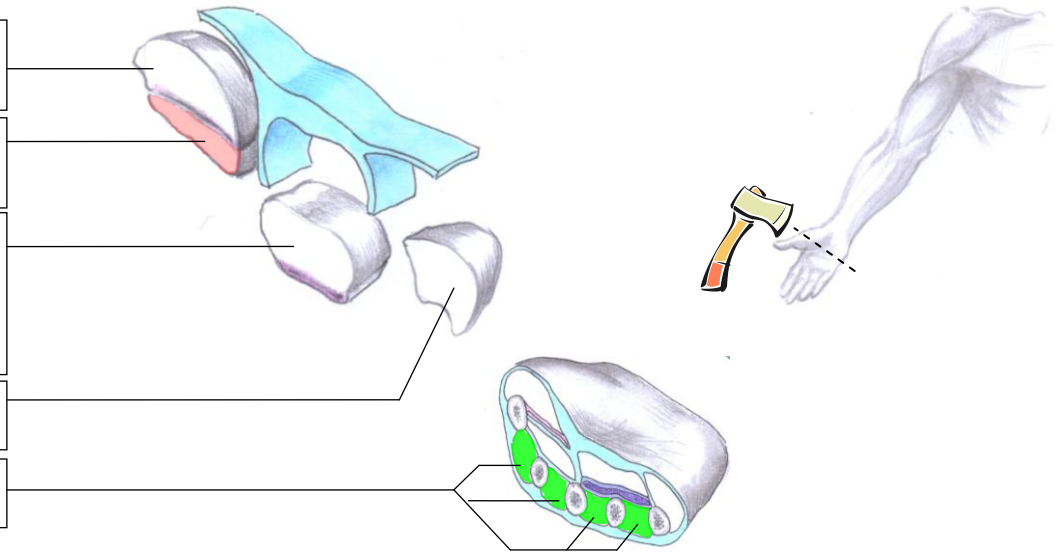


## Compartments of the palm and their contents

- Thenar compartment**  
Contains the thenar muscles
- Adductor compartment**  
Contains only Adductor Pollicis
- Central compartment**  
Contains the flexor tendons and their sheaths, the lumbricals, the superficial arterial palmar arch, and the digital vessels and nerves
- Hypothenar compartment**  
Contains the hypothenar muscles
- Interosseous compartments**  
Contains the interossei muscles



### Thenar Compartment

*Flexor Pollicis Brevis: Superficial head*  
which is innervated by the **MEDIAN NERVE**

*Deep Head* which is innervated by the  
**DEEP BRANCH OF THE ULNAR NERVE**

### Central Compartment

*1<sup>st</sup> and 2<sup>nd</sup> Lumbricals* which are unipennate and which are innervated by the **MEDIAN NERVE**  
*3<sup>rd</sup> and 4<sup>th</sup> Lumbricals* which are bipennate and which are innervated by the **DEEP BRANCH OF THE ULNAR NERVE**

*Abductor Pollicis Brevis*

*Opponens Pollicis*

*Adductor Pollicis*

### Adductor compartment

*Abductor Digiti Minimi*

### Hypothenar Compartment

*Opponens Digiti Minimi*

*Flexor Digiti Minimi Brevis*

*1<sup>st</sup> Dorsal Interossei*

*1<sup>st</sup> Palmar Interossei*

*2<sup>nd</sup> Dorsal Interossei*

*2<sup>nd</sup> Palmar Interossei*

*3<sup>rd</sup> Dorsal Interossei*

*3<sup>rd</sup> Palmar Interossei*

*4<sup>th</sup> Dorsal Interossei*

### Interosseous compartment

