

## Fascia and compartments of the shoulder

### PECTORALIS FASCIA

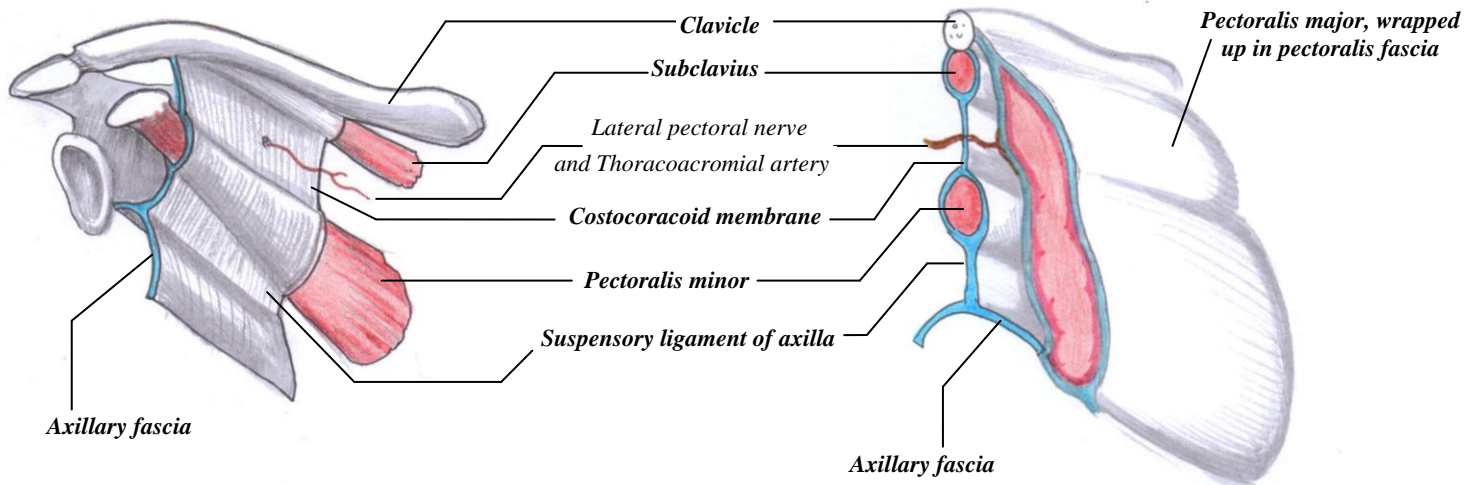
- The only contents is **Pectoralis Major**;
- Pectoralis fascia continue inferiorly as fascia of the anterior abdominal wall
- It continues laterally-once it leaves the lateral edge of Pectoralis Major, it becomes **AXILLARY FASCIA**

### AXILLARY FASCIA

- Continuous with the **CLAVIPECTORAL FASCIA**
- Forms the floor of the axilla

### CLAVIPECTORAL FASCIA

- Deep to the Pectoralis major muscle, the **CLAVIPECTORAL FASCIA** invests the **subclavius muscle** and **pectoralis minor**.
- It forms the **costocoracoid membrane** above pectoralis minor, and the **suspensory ligament of axilla** below pectoralis minor. The suspensory ligament drags the axillary fascia upwards when the arm is raised, forming the actual "pit" of the armpit

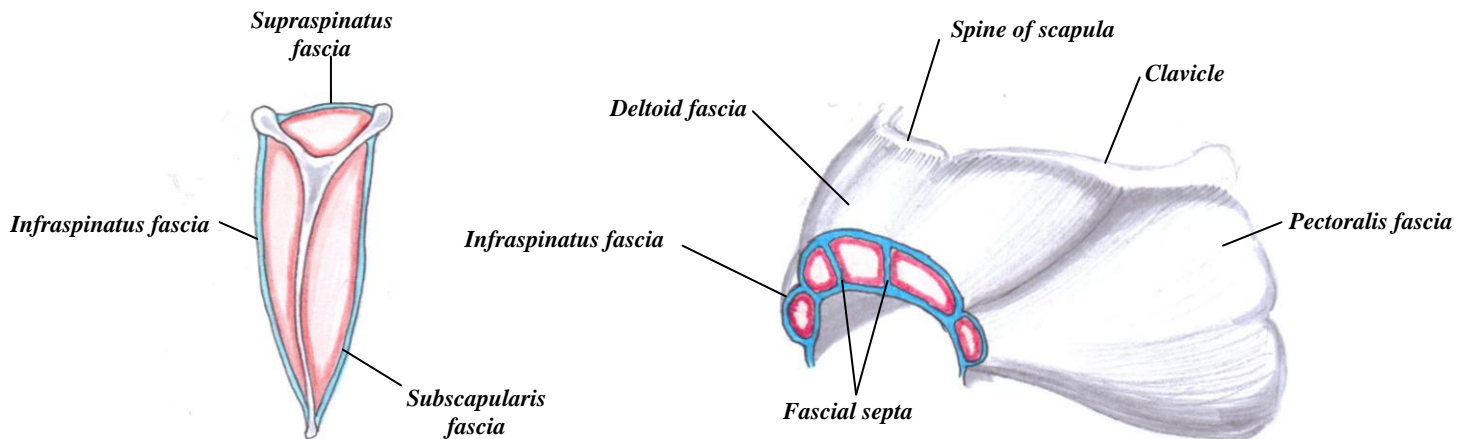


### Supraspinous, Infraspinous and Subscapular fascia

- The **supraspinatus**, **infraspinatus** and **subscapularis** muscles are contained in their own little fascial compartments

### Deltoid Fascia

- The **deltoid** has its own fascia, continuous with the pectoral fascia and infraspinatus fascia
- It has numerous fascial septa which separate the fascicles of the deltoid



Pectoralis fascia, infraspinatus fascia and deltoid fascia all continue down the arm to form the brachial fascia