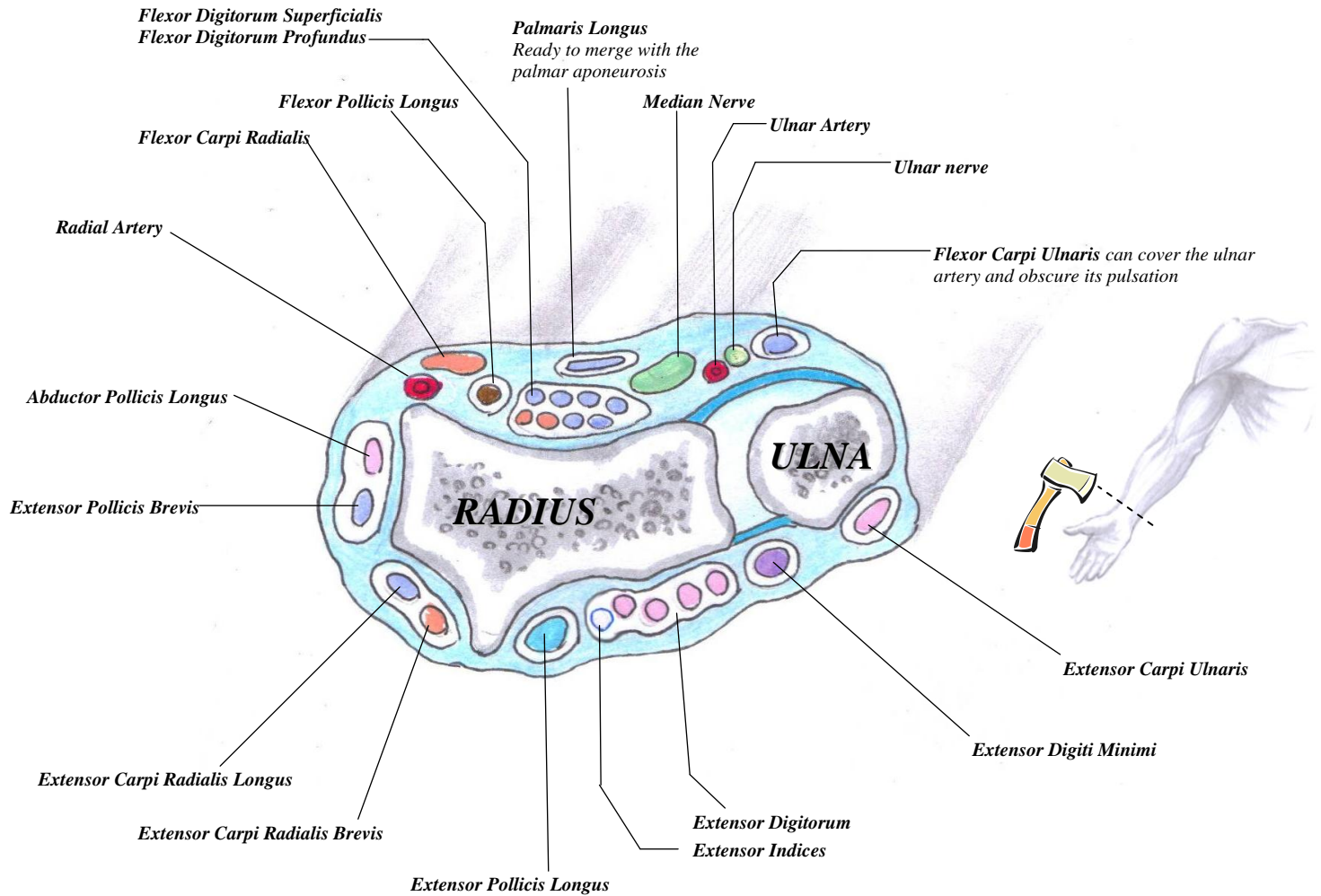


Flexor and Extensor Tendons at the Wrist: level of the Distal Radioulnar Joint



The Extensor Retinaculum

- Attaches to the lateral border of the radius
- Does NOT attach to the border of the ulna, because the ulna moves too much.
- Instead, attaches to the pisiform and the triquetrum
- Also attaches to the ridges of the radius, thus forming osseofibrous tunnels for the above tendons to run through
- There are 6 tunnels in total:
 1. One for abductor pollicis longus and extensor pollicis brevis
 2. One for extensor carpi radialis longus and extensor carpi radialis brevis
 3. One for extensor pollicis longus
 4. One for extensor digitorum and extensor indices
 5. One for extensor digiti minimi
 6. One for extensor carpi ulnaris