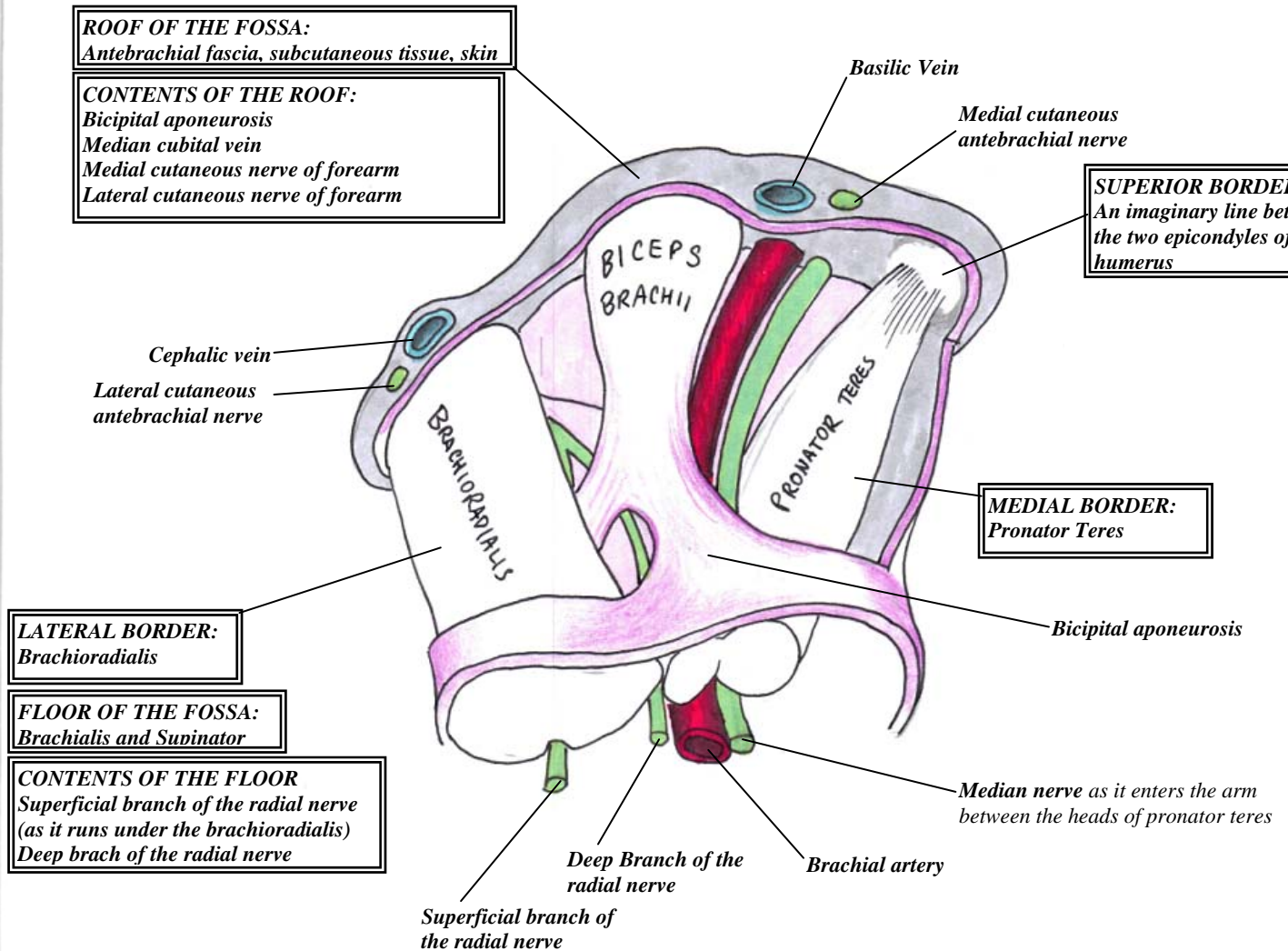


THE CUBITAL FOSSA



BOUNDARIES:

- **SUPERIORLY:** An imaginary line between the medial and lateral epicondyle
- **LATERALLY:** brachioradialis
- **MEDIAALLY:** Pronator teres
- **FLOOR:** brachialis and supinator
- **ROOF:** deep fascia, bicipital aponeurosis, median cubital vein, medial and lateral cutaneous nerves of the forearm

CONTENTS:

- Brachial artery
- Deep veins of the arm which accompany the brachial artery
- Biceps tendon
- Median nerve
- **SUPERFICIALLY:** median cubital vein, medial and lateral cutaneous nerve of the forearm
- **DEEP, in the floor:** deep and superficial branches of the radial nerve