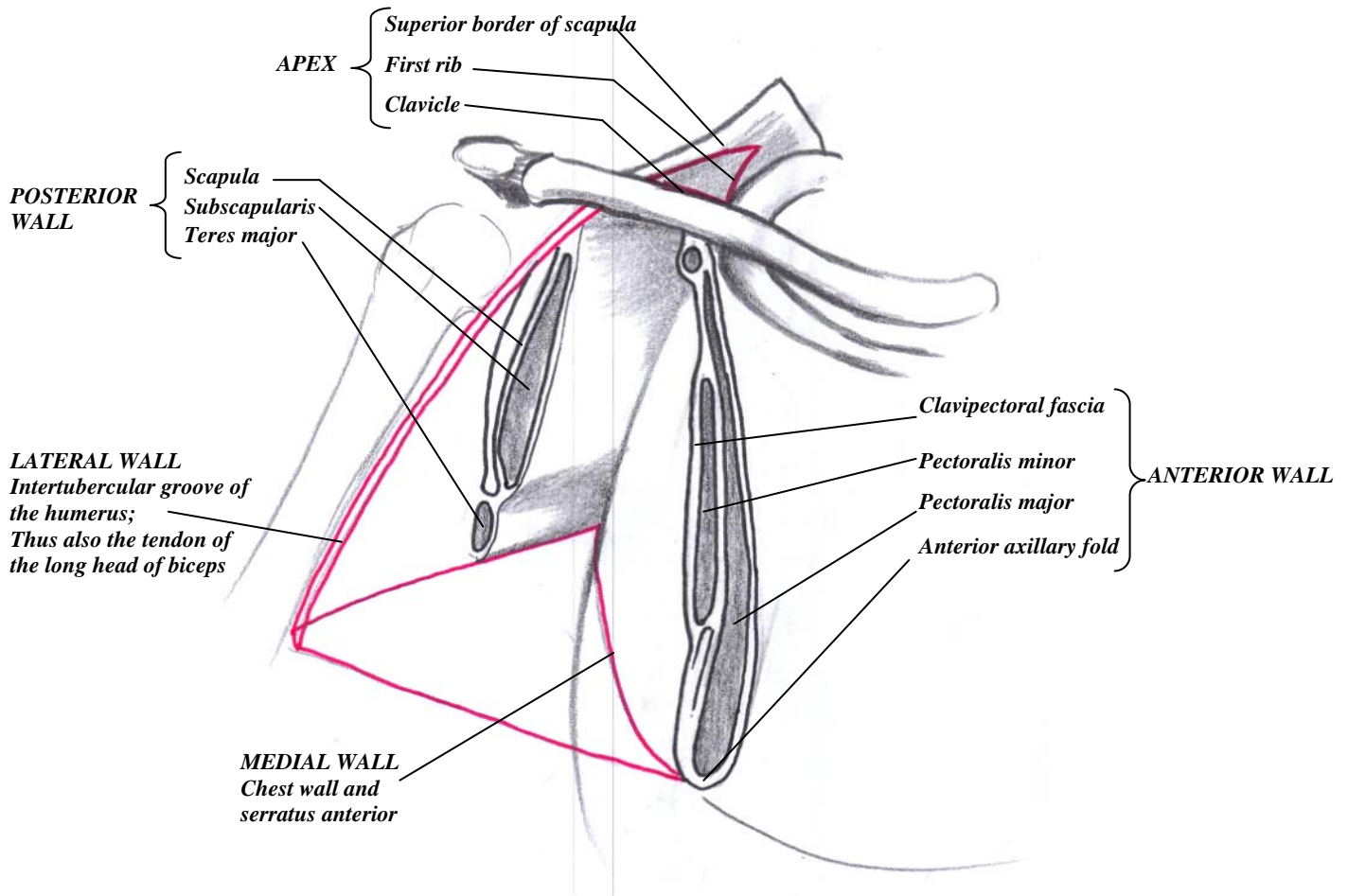


## THE AXILLA

- A PYRAMIDAL space: has a flat apex, 4 walls, and a base.



### CONTENTS

- Axillary artery and its branches
- Axillary vein and its tributaries- brachial vein, basilic vein and thoracoepigastric vein
- Lymphatic vessels and axillary lymph nodes
- Cords and branches of the brachial plexus

### BOUNDARIES

- **Apex**
  - Cervicoaxillary canal; passageway into the neck
  - Bounded by the 1<sup>st</sup> rib, clavicle, and superior edge of the scapula
  - The vessel and nerve's gateway into the arm
- **Base**
  - Axillary fossa: fat, fascia, skin
- **Anterior Wall-**
  - Pectoralis major, pectoralis minor, pectoral and clavipectoral fascia
  - The inferior part is the anterior axillary fold
- **Posterior wall -**
  - Scapula and subscapularis
  - Inferior border is the teres major and latissimus dorsi

### Medial wall -

- Rib cage, chest wall – ribs 1-4 and the intercostal muscles
- Serratus anterior

### Lateral wall -

- Narrow wall; intertubercular groove of the humerus