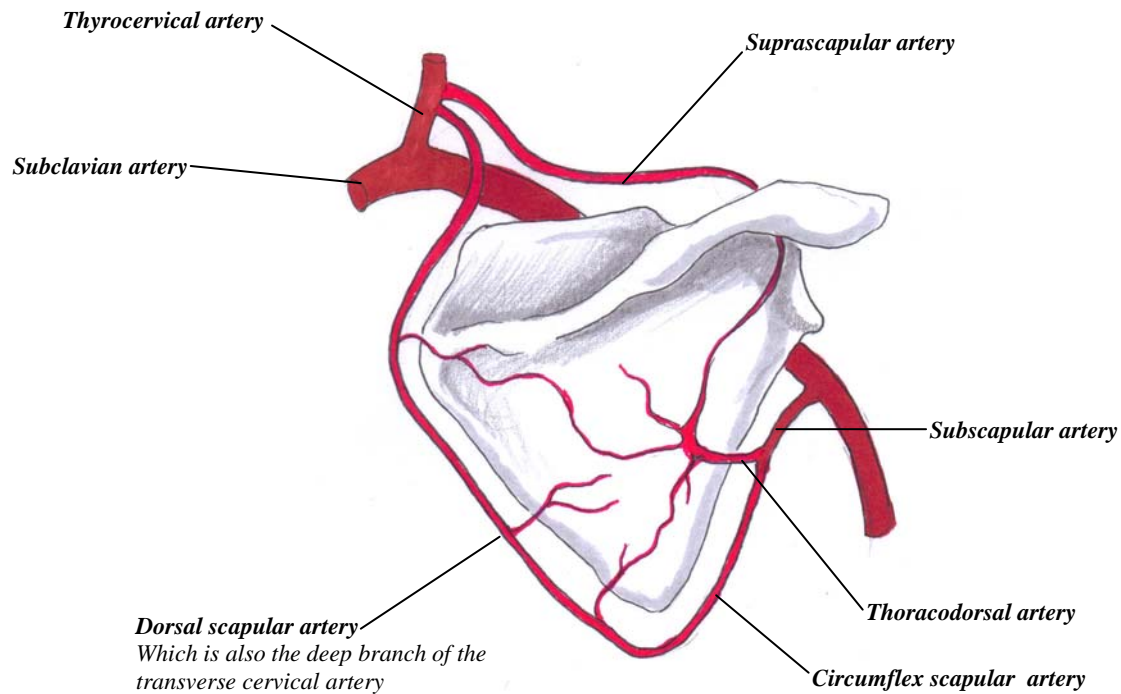


Arterial Anastomosis around the Scapula



This point is labored because:

If the axillary artery is cut or ligated, an adequate collateral blood supply will arrive to the arm via the dorsal scapular artery, and its anastomosis with the circumflex scapular artery.

However, if the axillary artery is ligated **BELOW** the third part of the axillary artery, there will not be any collaterals, and the arm will become ischaemic.