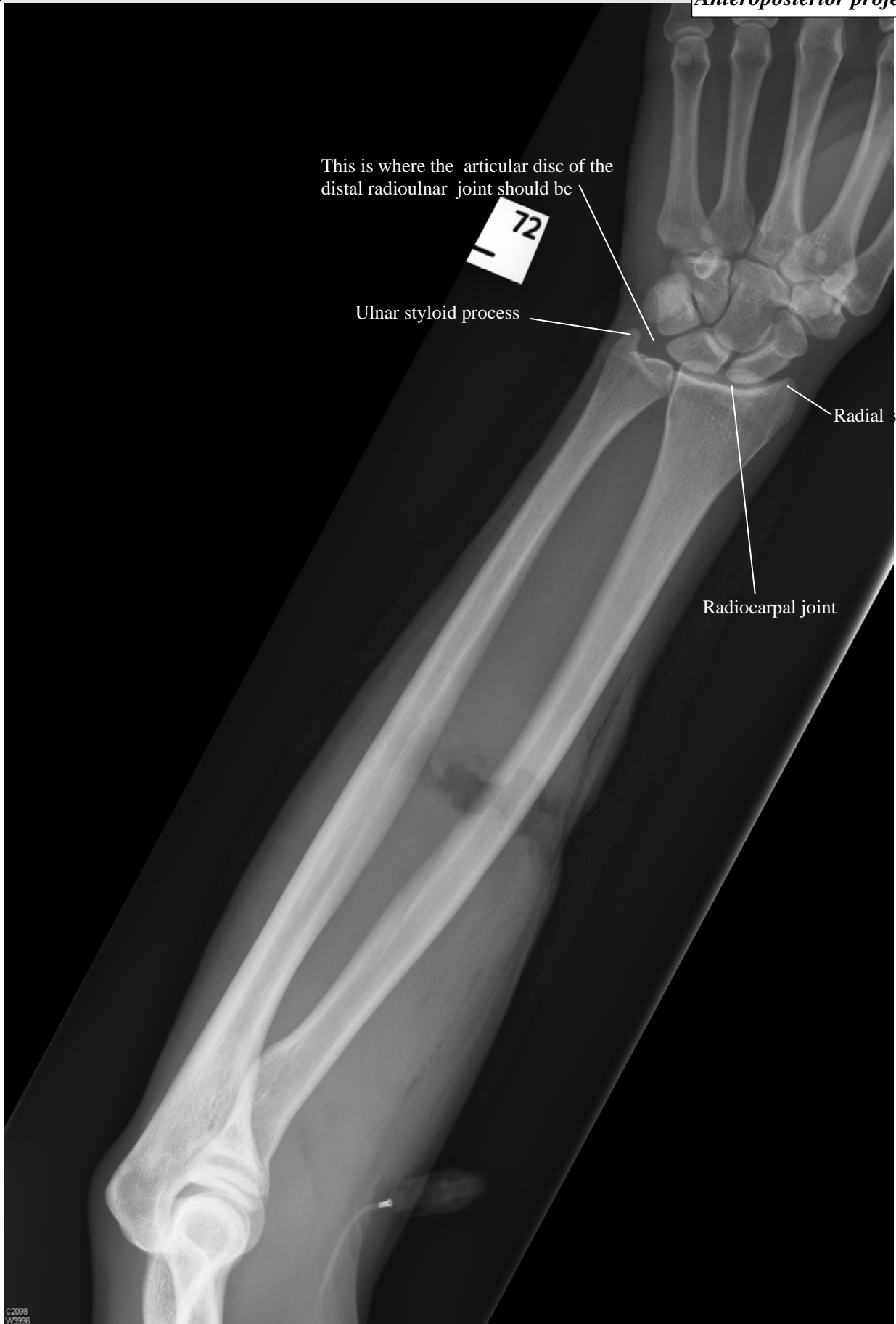


Xray of the Forearm

Anteroposterior projection



This is where the articular disc of the distal radioulnar joint should be

72

Ulnar styloid process

Radial styloid process

Radiocarpal joint